

This is a provisional PDF only. Copyedited and fully formatted version will be made available soon.



ISSN: 0015-5659

e-ISSN: 1644-3284

A unique variation of the jugular veins and its clinical significance

Authors: McKenzie Young, Alexis Zavitsky, Jillian Niceley, Gabriella Battiston, Sumathilatha Sakthi-Velavan

DOI: 10.5603/fm.98618

Article type: Case report

Submitted: 2023-12-23

Accepted: 2024-02-13

Published online: 2024-02-23

This article has been peer reviewed and published immediately upon acceptance. It is an open access article, which means that it can be downloaded, printed, and distributed freely, provided the work is properly cited.

Articles in "Folia Morphologica" are listed in PubMed.

CASE REPORT

A unique variation of the jugular veins and its clinical significance

McKenzie Young et al., **Variant veins of the neck**

McKenzie Young, Alexis Zavitsky, Jillian Niceley, Gabriella Battiston, Sumathilatha Sakthi-Velavan

Division of Biomedical Sciences, Marian University College of Osteopathic Medicine, Indianapolis, IN, 46222, USA

Address for orrespondence: Sumathilatha Sakthi-Velavan, Associate Professor of Anatomy, Division of Biomedical Sciences, Marian University College of Osteopathic Medicine, 3200 Cold Spring Rd, Indianapolis, IN 46222, USA; e-mail: ssakthivelavan@marian.edu, tel./fax : +1(317) [955-6245](tel:955-6245)

ABSTRACT

The authors report a rare variation of the anterior jugular and internal jugular veins in a 78-year-old male donor. An enlarged and curved left anterior jugular vein (AJV) was formed as the continuation of the left common facial vein (CFV). The left AJV's diameter was wider than the internal jugular vein (IJV) and measured around 5 mm greater than the IJV's diameter and a channel connected the two veins. The right AJV and CFV continued from the two divisions of the right facial vein. The right AJV's diameter was smaller than the right IJV's diameter. The right external jugular vein was absent. No concurrent pathology supported the abnormal dimension of the left AJV and the findings were indicative of a variant anatomy. These variations have rarely been reported and have important clinical correlations. Failed IJV cannulation may result if the variant neck veins are missed. However, variant veins may serve as collateral channels and patch material in IJV reconstruction, carotid angioplasty, and ventricular-jugular shunts.

Keywords: **jugular veins, anatomical variation, catheterization, venous anastomoses, communicating vein, bilateral variation**

INTRODUCTION

The veins of the head and neck drain the brain, face, and neck [1]. The anterior jugular vein (AJV), formed by the confluence of submandibular veins near the midline, drains into the external jugular vein (EJV) or subclavian vein (SCV) [2]. The internal jugular vein (IJV), the continuation of sigmoid sinus, terminates by uniting with the SCV to form the brachiocephalic vein [2]. The facial vein (FV) unites with the anterior division of the retromandibular vein (RMV) to form the common facial vein (CFV) which drains into the IJV [2]. The posterior division of the RMV unites with the posterior auricular vein to form the EJV which drains into the SCV [2].

Anatomical variations of neck veins are common because of the region's robust vascular network [3]. A clear understanding of the venous variations helps prevent complications like pneumothorax, muscular damage, and carotid artery puncture during procedures [1, 4]. Commonly reported variations in the superficial neck veins include the EJV (most variable), posterior EJV, AJV, and the thyroid veins [1]. Studies reported 26% of 104 patients had either a unilateral or bilateral IJV variation, 0.3 to 2.0% of 330 patients had facial vein (FV) variations, and 6 of 35 (17.1%) donors had CFV variations [3, 5, 6]. This case report explores a unique course and drainage of the AJV and CFV bilaterally, and their clinical significance.

CASE REPORT

An atypical variation in the formation, dimensions, and the drainage of the left anterior jugular vein was observed in a 78-year-old male donor during routine dissection in the anatomy laboratory. Detailed dissection preserving the veins and related neurovasculature was implemented. The origin, drainage, and tributaries of other neck veins, were explored. The IJV was traced to the cranial cavity and the intracranial sinuses were examined. The enlarged neck veins were opened and the lumina were examined for thrombosis or other pathology. The veins were painted blue with acrylic paint (Apple Barrel Matte Bright Blue Acrylic Craft Paint) and photographed. The vein circumferences were measured using digital calipers at the level of the thyroid cartilage, and diameters were calculated using the equation, $\text{circumference} / \pi$ (Table 1).

The left AJV was found to be greatly enlarged and curved on the anterolateral aspect of the neck. It was formed as the continuation of the left CFV and a communicating vein connected it to the left IJV (Figs. 1, 3B). The left AJV united with the left EJV before draining into the SCV at the level of the clavicle. The left IJV was smaller than the left AJV and its counterpart on the right. A communicating vein connected the left AJV and IJV. The left EJV was the continuation of the posterior division of the RMV, while the anterior division of RMV joined the facial vein to form the CFV. The right jugular system differed from the left. The right AJV appeared normal and measured smaller than the left AJV. The right FV terminated as two divisions (Figs. 2, 3A). The posterior division continued as the right CFV, while the anterior division continued as the AJV. Like the left

side, a communicating channel connected the AJV and IJV. The right IJV appeared dilated. The right EJV was absent. The lumina of neck veins showed no pathology.

DISCUSSION

The head and neck veins begin developing in the embryo during week 4 from the cardinal venous system [2]. The ventral pharyngeal vein (VPV), which drains the mandibular and hyoid arches, is the first recognizable vein [2]. The VPV drains into the anterior cardinal vein, which becomes the IJV [2]. Several venous channels from face and neck drains into the IJV [2]. A capillary plexus from the neck forms the EJV [2]. The convergence of the superficial submandibular veins forms the AJVs, which empty into the EJVs [2]. The variant anatomy noted in this case may be due to the lack of or malformation of the venous anastomotic channels.

Nayak reported a case in which the FV continued as the AJV in the presence of a communicating vein between the AJV and IJV, unilaterally [7]. Kumar and Baidya reported a case in which the CFV continued as the AJV with no communicating vein between the IJV and AJV, unilaterally [8]. However, this case is unique since bilateral variations with the left CFV and the anterior division of the right FV continuing as the left and right AJV respectively were present.

The dimensions of the IJVs and left AJV in this case were noteworthy. Tartièrè et al. found that the right IJV was larger than the left in 75 to 80% of 190 adult patients [9]. The mean diameter of the right IJV was 17 ± 5 mm, and the mean diameter of the left IJV was 14 ± 5 mm at the level of the cricoid cartilage [9]. In this case, the right IJV was larger than the left IJV, supporting the study. However, the right IJV had a larger than normal diameter above the cricoid cartilage, and the left IJV had a smaller than normal diameter (Table 1). Hojaij et al. reported that the AJV's diameter was ≥ 5 mm in 40% of 30 cadavers studied; however, the AJV is typically smaller than the other jugular veins [2, 10]. In this case, the left AJV was larger than the other jugular veins on the left (Table 1) which was likely due to its communication with the other veins.

Enlarged superficial veins may indicate a pathological process [7, 11]. Additionally, if the AJV is larger than the EJV, then thrombosis of the EJV may be present [7, 11]. However, no evidence of thrombosis was found in this case, which is suggestive of a variant anatomy [11]. It is likely that the enlarged right IJV and left AJV formed secondary to the smaller left IJV to provide adequate drainage of the head and neck. An absent EJV, as noted on the right side of this donor, may be due to the lack of or malformation of anastomotic channels, such as that between the cephalic vein and FV [2, 12]. In the case of an absent EJV, the veins that typically form the EJV open into the IJV as noted in this case [12].

Catheter mispositioning or failed IJV cannulation may result if the variant superficial veins are not noted [11]. Utilizing ultrasound may help differentiate the IJV from a prominent AJV during

cannulation, to prevent unintentional injury [11]. A discernible AJV may serve as a collateral pathway for intracranial venous drainage [11]. Specifically, in the case of unilateral occlusion of brachiocephalic vein and when performing IJV reconstruction, an enlarged AJV is considered useful [11, 13]. Normally, the union of the CFV and IJV is just superior to the carotid bifurcation, providing the surgeon with a consistent landmark [4]. Adequate and accurate access to the bifurcation is essential because it is the most common location of atherosclerosis [14]. When the left CFV does not unite with the IJV, as noted in this case, it cannot be used as an accurate landmark.

During carotid angioplasty and endarterectomy, the anterior border of IJV may be helpful in locating the incision site to open the carotid sheath [4]. While an enlarged IJV helps in an easier localization of incision site, it poses an increased risk of injury to the IJV compared to a procedure with a normal or smaller IJV. During cannulation, the right IJV is preferred because it provides direct access to the superior vena cava, is more commonly the dominant hand side, has a lower complication rate, and is typically larger than the left IJV [9]. The larger than normal right IJV, as noted in this donor, provides easier access for cannulation.

CONCLUSIONS

The presence of variant head and neck veins, reported in this case, can complicate patient care while also providing alternatives if other pathologies or variations are not noted. Without knowledge of a patient's variant anatomy, the physician may not be successful in cannulation, catheterization, carotid angioplasty and endarterectomy, and other procedures.

Article information and declarations

Ethics statement

The Marian University Institutional Review Board declared that the study did not need review or approval and cleared the study since the research was on a cadaver (IRB#B23.109).

Author contributions

McKenzie Young: Study conception, design, dissection, data collection, manuscript preparation and review and preparation of figures 1, 2, and 3.

Alexis Zavitsky: Study conception, design, dissection, data collection, manuscript preparation and review and preparation of table 1.

Jillian Niceley: Study conception, design, manuscript preparation and review and preparation of Table 1.

Gabriella Battiston: Study conception, design, manuscript preparation and review.

Sumathilatha Sakthi-Velavan: Conceptualization, guidance, reviewing, editing and funding acquisition.

Acknowledgments

The authors would like to thank the donor and his family for their generosity so that anatomical research could be performed. The authors also thank Marian University College of Osteopathic Medicine for the support in conducting the research.

Conflict of interest

The authors declare no conflict of interest.

Funding

The study was supported by the Marian University Research & Scholarship Administration.

REFERENCES

1. Dalip D, Iwanaga J, Loukas M, et al. Review of the variations of the superficial veins of the neck. *Cureus*. 2018; 10(6): e2826, doi: [10.7759/cureus.2826](https://doi.org/10.7759/cureus.2826), indexed in Pubmed: [30131919](https://pubmed.ncbi.nlm.nih.gov/30131919/).
2. Standring S. Development of the head and neck. In: Standring S. ed. *Gray's anatomy: the anatomical basis of clinical practice*. Elsevier Churchill Livingstone, Edinburgh 2021: 273–291.
3. Bertha A, Rabi S. Anatomical variations in termination of common facial vein. *J Clin Diagn Res*. 2011; 5(1): 24–27.
4. Gupta V, Tuli A, Choudhry R, et al. Facial vein draining into external jugular vein in humans: its variations, phylogenetic retention and clinical relevance. *Surg Radiol Anat*. 2003; 25(1): 36–41, doi: [10.1007/s00276-002-0080-z](https://doi.org/10.1007/s00276-002-0080-z), indexed in Pubmed: [12819948](https://pubmed.ncbi.nlm.nih.gov/12819948/).
5. Bondaz M, Ricard AS, Majoufre-Lefebvre C, et al. Facial vein variation: implication for facial transplantation. *Plast Reconstr Surg Glob Open*. 2014; 2(7): e183, doi: [10.1097/GOX.000000000000134](https://doi.org/10.1097/GOX.000000000000134), indexed in Pubmed: [25426366](https://pubmed.ncbi.nlm.nih.gov/25426366/).
6. Lin BS, Kong CW, Tarng DC, et al. Anatomical variation of the internal jugular vein and its impact on temporary haemodialysis vascular access: an ultrasonographic survey in uraemic patients. *Nephrol Dial Transplant*. 1998; 13(1): 134–138, doi: [10.1093/ndt/13.1.134](https://doi.org/10.1093/ndt/13.1.134), indexed in Pubmed: [9481729](https://pubmed.ncbi.nlm.nih.gov/9481729/).
7. Nayak BS. Surgically important variations of the jugular veins. *Clin Anat*. 2006; 19(6): 544–546, doi: [10.1002/ca.20268](https://doi.org/10.1002/ca.20268), indexed in Pubmed: [16372344](https://pubmed.ncbi.nlm.nih.gov/16372344/).
8. Kumar S, Baidya R. Termination of the common facial vein into the anterior jugular vein: a rare case report. *Int J Anat Res*. 2018; 6(3.2): 5501–5503, doi: [10.16965/ijar.2018.255](https://doi.org/10.16965/ijar.2018.255).
9. Tartièrè D, Seguin P, Juhel C, et al. Estimation of the diameter and cross-sectional area of the internal jugular veins in adult patients. *Crit Care*. 2009; 13(6): R197, doi: [10.1186/cc8200](https://doi.org/10.1186/cc8200), indexed in Pubmed: [20003190](https://pubmed.ncbi.nlm.nih.gov/20003190/).

10. Hojaij FC, Santos L, Moyses R, et al. Anatomy of the anterior jugular veins: anatomical study of 30 cadavers. *Arch Head Neck Surg.* 2022; 51: e20220005, doi: [10.4322/ahns.2022.0005](https://doi.org/10.4322/ahns.2022.0005).
11. Schummer W, Schummer C, Bredle D, et al. The anterior jugular venous system: variability and clinical impact. *Anesth Analg.* 2004; 99(6): 1625–1629, doi: [10.1213/01.ANE.0000138038.33738.32](https://doi.org/10.1213/01.ANE.0000138038.33738.32), indexed in Pubmed: [15562044](https://pubmed.ncbi.nlm.nih.gov/15562044/).
12. Cvetko E. A case of left-sided absence and right-sided fenestration of the external jugular vein and a review of the literature. *Surg Radiol Anat.* 2015; 37(7): 883–886, doi: [10.1007/s00276-014-1398-z](https://doi.org/10.1007/s00276-014-1398-z), indexed in Pubmed: [25432662](https://pubmed.ncbi.nlm.nih.gov/25432662/).
13. Katsuno S, Ishiyama T, Nezu K, et al. Three types of internal jugular vein reconstruction in bilateral radical neck dissection. *Laryngoscope.* 2000; 110(9): 1578–1580, doi: [10.1097/00005537-200009000-00034](https://doi.org/10.1097/00005537-200009000-00034), indexed in Pubmed: [10983966](https://pubmed.ncbi.nlm.nih.gov/10983966/).
14. De Syo D, Franjić BD, Lovricević I, et al. Carotid bifurcation position and branching angle in patients with atherosclerotic carotid disease. *Coll Antropol.* 2005; 29(2): 627–632, indexed in Pubmed: [16417173](https://pubmed.ncbi.nlm.nih.gov/16417173/).

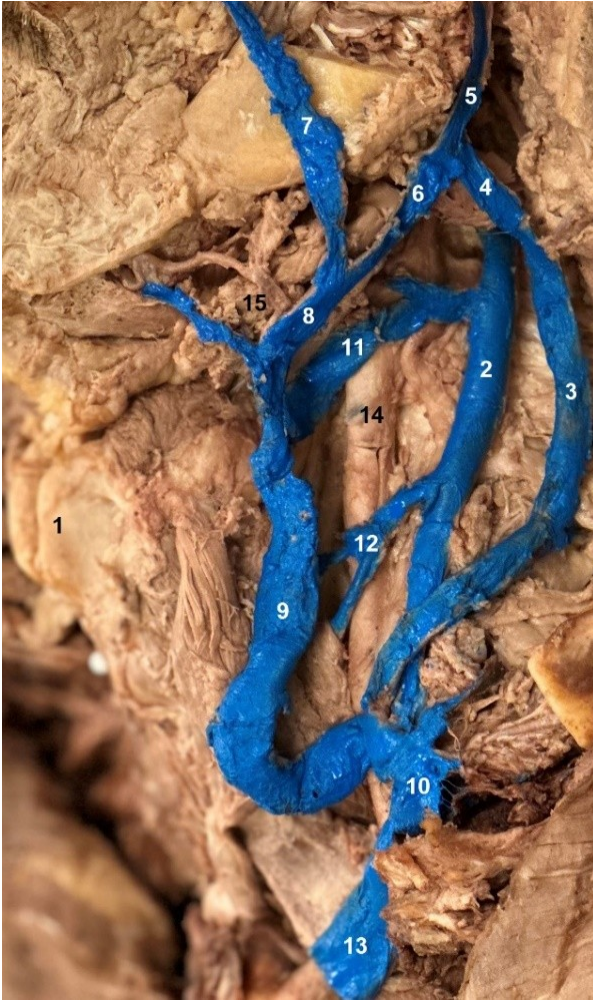

Figure 1. Left head and neck venous system, 1 — thyroid cartilage, 2 — internal jugular vein, 3 — external jugular vein, 4 — posterior division of retromandibular vein, 5 — retromandibular vein, 6 — anterior division of retromandibular vein, 7 — facial vein, 8 — common facial vein, 9 — anterior jugular vein, 10 — subclavian vein, 11 — communicating vein between IJV and AJV, 12 — common trunk of superior and middle thyroid veins, 13 — brachiocephalic vein, 14 — common carotid artery, 15 — submandibular gland.

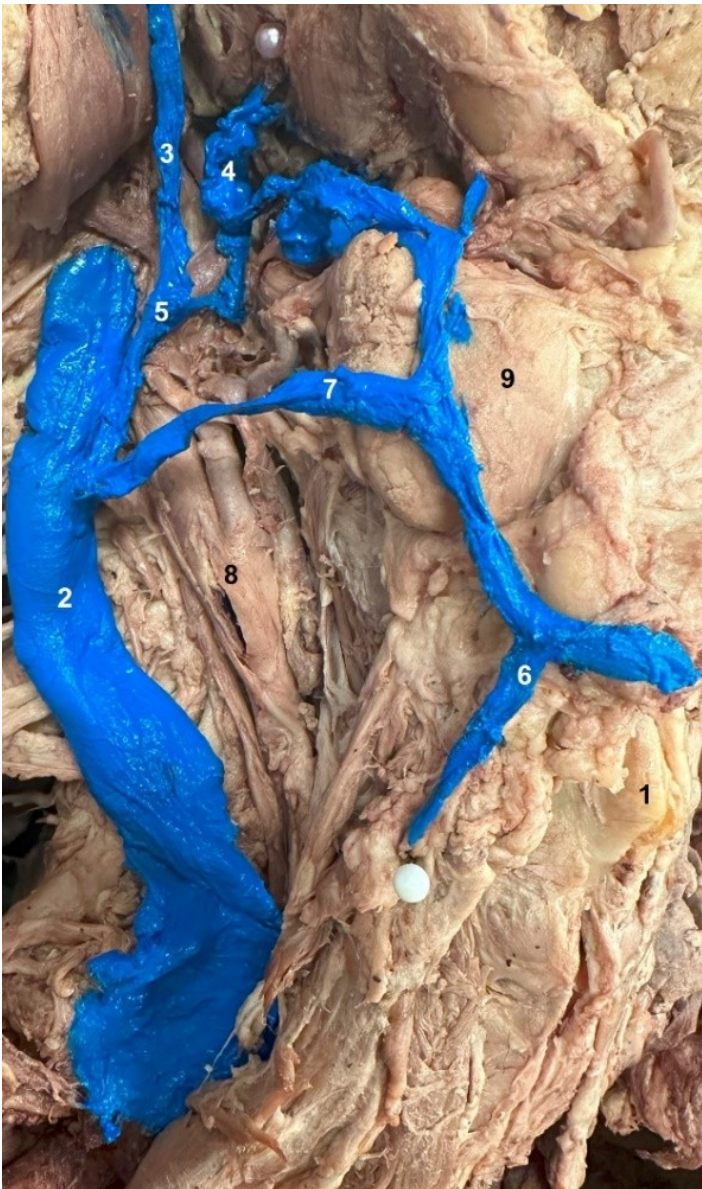

Figure 2. Right head and neck venous system, 1 — thyroid cartilage, 2 — internal jugular vein, 3 — retromandibular vein, 4 — facial vein, 5 — common facial vein, 6 — anterior jugular vein, 7 — communicating vein between IJV and AJV, 8 — common carotid artery, 9 — submandibular gland.

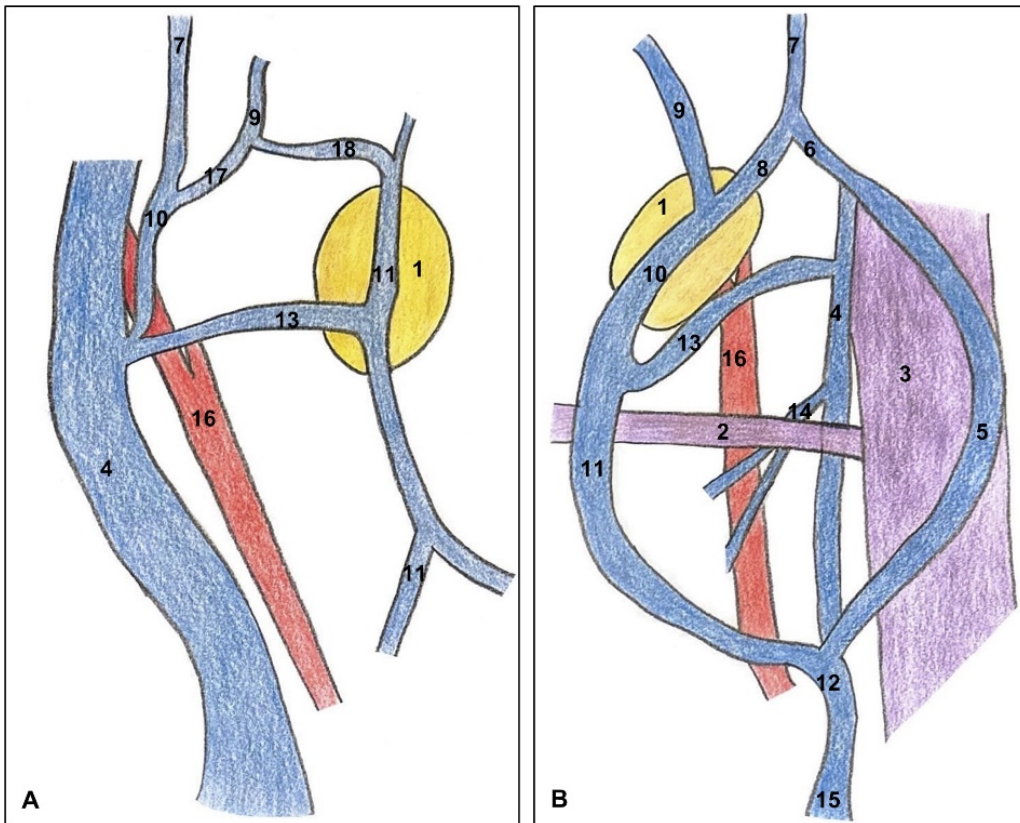


Figure 3. A. Schematic of right head and neck venous system, B. Schematic of left head and neck venous system. 1 — submandibular gland, 2 — omohyoid, 3 — sternocleidomastoid, 4 — internal jugular vein, 5 — external jugular vein, 6 — posterior division of retromandibular vein, 7 — retromandibular vein, 8 — anterior division of retromandibular vein, 9 — facial vein, 10 — common facial vein, 11 — anterior jugular vein, 12 — subclavian vein, 13 — communicating vein between IJV and AJV, 14 — common trunk of superior and middle thyroid veins, 15 — brachiocephalic vein, 16 — common carotid artery, 17 — posterior division of facial vein, 18 — anterior division of facial vein.

Table 1. Jugular vein measurements.

	Diameter at the level of thyroid cartilage	Diameter at the level of angle of mandible
Left		
AJV	8.91 mm	—
IJV	3.82 mm	2.55 mm
EJV	5.10 mm	—
Right^a		
AJV	1.91 mm	—
IJV	15.92 mm	11.46 mm

^aNo EJV was observed on the right side.

AJV — anterior jugular vein; EJV — external jugular vein; IJV — internal jugular vein